

LETTER TO THE EDITOR

USE OF PHOTOBIOMODULATION INDUCED BY POLARIZED POLYCHROMATIC NON-COHERENT LIGHT IN THE MANAGEMENT OF ADULT CHRONIC PERIODONTITIS

G.M. NARDI¹, R. GRASSI², F.R. GRASSI³, S.E. ARAGONA⁴, B. RAPONE³,
F. DELLA VELLA³ and S. SABATINI¹

¹Department of Odontostomatological and Maxillofacial Sciences, University of Rome "Sapienza", Rome, Italy; ²Department of Clinical and Experimental Medicine, Medical, Surgical and Experimental Sciences, University of Sassari, Sassari, Italy; ³Department of Basic Medical Sciences, Neurosciences and Sense Organs, University of Bari "Aldo Moro", Bari, Italy; ⁴Humanitas Mater Domini Hospital, Castellanza (VA), Italy

Received June 7, 2018 – Accepted November 20, 2018

The aim of the study was to evaluate the efficacy of a polarized, polychromatic, non-coherent light (Bioptron), in addition to full mouth scaling and root planing, in chronic periodontitis. Forty adult patients affected by chronic periodontitis were enrolled in the study and were randomly divided into two groups. The control group received only full mouth scaling and root planing (FMSRP), while in the test group, Bioptron light treatment was added to FMSRP. The Full Mouth Plaque Score (FMPS), Full Mouth Bleeding Score (FMBS), Gingival Index (GI) and Probing Pockets Depth (PPD) were recorded in both groups at the first examination, after 1 month (T1) and after 3 months (T2). Both groups showed a significant reduction of FMPS at T1 and T2 ($p < 0.05$). Both groups showed a significant reduction of FMBS at T1 and T2 ($p < 0.05$), but a higher improvement ($p < 0.05$) was recorded in the study group at T1. Study group GI was significantly reduced at T2 ($p < 0.05$), differently from the control group ($p > 0.05$). PPD showed a reduction in both groups with no statistically significant differences ($p > 0.05$) between them. Polarized, polychromatic non-coherent light seems to be an effective additional therapy in the management of adult chronic periodontitis, reducing inflammatory clinical indexes.

To the Editor,

Periodontitis is an infective-immune-inflammatory disease characterized by the loss of tooth-supporting structures, including the connective tissue attachment and the alveolar bone (1). It is reported that 10-15% of the worldwide adult population is affected by periodontitis (2). This condition can be chronic or acute, generalized or localized, and can lead to gingival inflammation and bleeding, progressive attachment loss with probing pocket depth.

Full mouth scaling and root planing (FMSRP) represent the gold standard in periodontal therapy in order to remove plaque and subgingival bacterial biofilm, which play the major role in the disease initiation and progression (1). Periodontal therapy is also aimed to provide long-term improvement in clinical parameters, including inflammation relief, reduction of gingival bleeding and probing pocket depth, and gain in attachment level (3). Providing patients with customized care protocols to be carried out at home, is a key aspect

Key words: light therapy; chronic periodontitis; periodontal therapy

Corresponding Author:

Prof. Gianna Maria Nardi,
Università Sapienza di Roma,
Dipartimento di Scienze Odontostomatologiche
e Maxillo Facciali, Via Caserta 6, 00161 Roma, Italy
Tel.: +39 3938368151
e-mail: giannamaria.nardi@uniroma1.it

of modern periodontal treatment (4). Increased health awareness and improvements in preventive dentistry and in minimally invasive therapies have led to a decrease in tooth loss. Increased life expectancy and greater health expectations lead to changes in demand of individuals of all age groups for periodontal treatment and a substantial increase in periodontal therapy. New aims can be reached in terms of accelerating wound healing, reducing more clinical indexes and improving patient comfort. Different adjunctive therapies to treat periodontal patients have been proposed in the literature (5, 6). Polarized, polychromatic, non-coherent light is used in medicine for the treatment of a wide range of medical conditions, including carpal tunnel syndrome (7), epicondylalgia (8), and chronic ulcers (9, 10).

Polarized, polychromatic, non-coherent light induces activation and modulation of biological processes, promoting anti-inflammatory, antibacterial and regenerative endogen mechanisms.

The increase of nitric oxide production, modulation of cytokine secretion, and effects on the vessels and on collagen metabolism are the key biological aspects controlled by the light application (10).

MATERIALS AND METHODS

Inclusion criteria

Forty consecutive adult patients referred to a private practice in Rome were included in this study. All the patients enrolled had received a diagnosis of generalized chronic periodontitis (more than 30% of total sites with no reversible attachment loss). The study was conducted in accordance with the Declaration of Helsinki, and all participants provided written and informed consent before participation.

Exclusion criteria

Patients assuming antibiotics or NSADs in the previous month, pregnant or nursing, and patients with previous diagnosis of melanoma were excluded.

The included patients were randomly divided in a test group and a control group using a randomization software (<https://www.randomizer.org>).

Periodontal protocol

Full Mouth Plaque Score (FMPS) was collected at the

beginning of the study (T0). According to Dental Biofilm Detection Topographic Technique (D-Biotech) protocol, fluorescein plaque detector was applied and highlighted with VALO LED curing light to facilitate FMPS recording and plaque removal. After FMPS recording, a deplaquing procedure was performed with Chlorhexidine (CHX) 0.2% mouthwash (Corsodyl[®], GSK) for one minute. Each tonsil was reached with one CHX spray (Corsodyl[®], GSK). Airpolishing (Mectron[®] Combi touch) was applied only where plaque was highlighted with a 90° angled tip for occlusal and buccal surfaces and with a 120° angled tip for palatal and lingual surfaces.

Full Mouth Bleeding Score (FMBS), Gingival Index (GI) and Probing Pocket Depth (PPD) were collected with a PCP 15 UNC periodontal probe.

FMSRP was performed using Mectron[®] Combi touch and curesets. S1 ultrasonic universal tip and manual scaler M23 slim was used for supragingival scaling. P10 ultrasonic periodontal tip and Queen of Hearts universal curette were used for all PPD \geq 4 mm sites. Periopolishing with glycine powder was performed.

Once the FMSRP was completed, the test group patients received an application of polarized polychromatic non-coherent light (Biopton B2 device, Biopton AG, Menfi Industry S.P.A.). Biopton light was held at 90° at 10 cm in front of the buccal area of the incisors, as this is reported to achieve maximal penetration of light, for exactly 10 min. A transparent cheek retractor (Directa[®]) was used to keep gums well exposed. Biopton light had the following output characteristics: rated power of halogen = 90 W; light wavelength = 480–3400 nm; degree of polarization = 95%; specific power density = 40 mW/cm²; and energy density = 2.4 J/cm². Treatment duration was 10 min every 7, 14, 21 days. Control group patients received no additional treatment at FMSRP.

Each patient received the same periodontal domiciliary indications, according to the Tailored Brushing Method (TBM). For the first 7 days, patients were asked to brush twice per day for two min with a soft bristles toothbrush (Gum Technique Pro Compact Soft) and a specific toothpaste for bleeding gums (Parodontax[®]). The tongue was brushed for at least 15 s and oral hygiene was completed with a 0.2% CHX mouthwash for 1 min. After 7 days, patients were asked to brush twice per day with a medium bristle toothbrush (Gum Technique Pro Compact Medium) for two min at least with a protective toothpaste

for exposed roots (Sensodyne Repair and Protect®). The tongue was brushed for at least 15 sec. Clinical scores (FMPS, FMBS, GI, PPD) were recorded after 1 month (T1) and after 3 months (T2).

Statistical analysis

Student's *t*-test was used to compare clinical indexes of the Study group and the Control Group at T0, T1 and T2. Graph Pad software T Test Calculator was used to perform the analyses.

RESULTS

Forty patients (20 in the study group and 20 in the control group) were enrolled, 17 women and 23 men. Overall mean age was 53±11 years (47±4 for women and 54±10 for men). At baseline, no statistically significant differences were found between the mean clinical indexes of both groups. None of the patients enrolled dropped out the study. In Table I are resumed the clinical indexes collected in the study. The study flow chart is reported in Fig. 1.

FMPS in the study group was 31.7% at T0, 13% at T1 and 14.3% at T2. The same index in the control group was 34.5% at T0, 14% at T1 and 17.3% at T2. The FMPS reduction was statistically significant in both groups at both times of observation ($p=0.001$). There was no

statistically significant difference between the two groups at T1 ($p>0.05$) and at T2 ($p>0.05$).

FMBS in the study group was 38.1% at T0, 16.3% at T1 and 13.7% at T2. The FMBS reduction was statistically significant both at T1 and T2 ($p<0.05$). FMBS in the control group was 41% at T0, 15.7% at T1 and 16.3% at T2. The FMBS reduction was statistically significant both at T1 and T2 ($p<0.05$). The difference between the two group was statistically significant only at T1 ($p<0.05$).

GI in the study group was 2.7 at T0, 2 at T1 and 1.5 at T2. The reduction was better at T2 than at T1 ($p<0.05$). GI in the control group was 2.9 at T0, 2.1 at T1 and 2.8 at T2. The reduction was statistically significant only at T1 ($p<0.05$), while at T2 the index was higher compared to T1. There was a statistically significant difference between the 2 groups at T2.

PPD in the study group was 5.6 at baseline, 4.9 at T1 and 4.2 at T2. PPD in the control group was 5.9 at baseline, 5.1 at T1 and 4.3 at T2. The reduction was statistically significant in both groups only at T2 ($p<0.05$), but there was no statistically significant difference between the 2 groups ($p>0.05$). No side effects were reported.

DISCUSSION

Adjunctive treatment with Bioptron light in periodontal patients can accelerate the healing process, with a faster

Table I. Comparison of clinical indexes for test group and control group.

		T0	T1	T2	T0-T1		T0-T2	
					value	p	value	p
FMPS	Study group	31.7%	13%	14.3%	-18.5	0.001	-17.4	0.001
	Control group	34.5%	14%	17.3%	-20.5	0.001	-17.2	0.001
	p	Ns	Ns	Ns	Ns		Ns	
FMBS	Study group	38.1%	16.3%	13.7%	-21.8	0.001	-24.4	0.001
	Control group	41%	15.7%	16.3%	-25.3	0.001	-24.7	0.001
	p	Ns	Ns	Ns	0.001		Ns	
GI	Study group	2.7	2	1.5	-0.7	0.001	-1.2	0.001
	Control group	2.9	2.1	2.8	-0.8	0.001	-0.1	Ns
	p	Ns	Ns	0.001	Ns		0.001	
PPD	Study group	5.6	4.9	4.2	-0.7	Ns	-1.4	0.001
	Control group	5.9	5.1	4.3	-0.8	Ns	-1.6	0.001
	p	Ns	Ns	Ns	Ns		Ns	

Ns: not significant

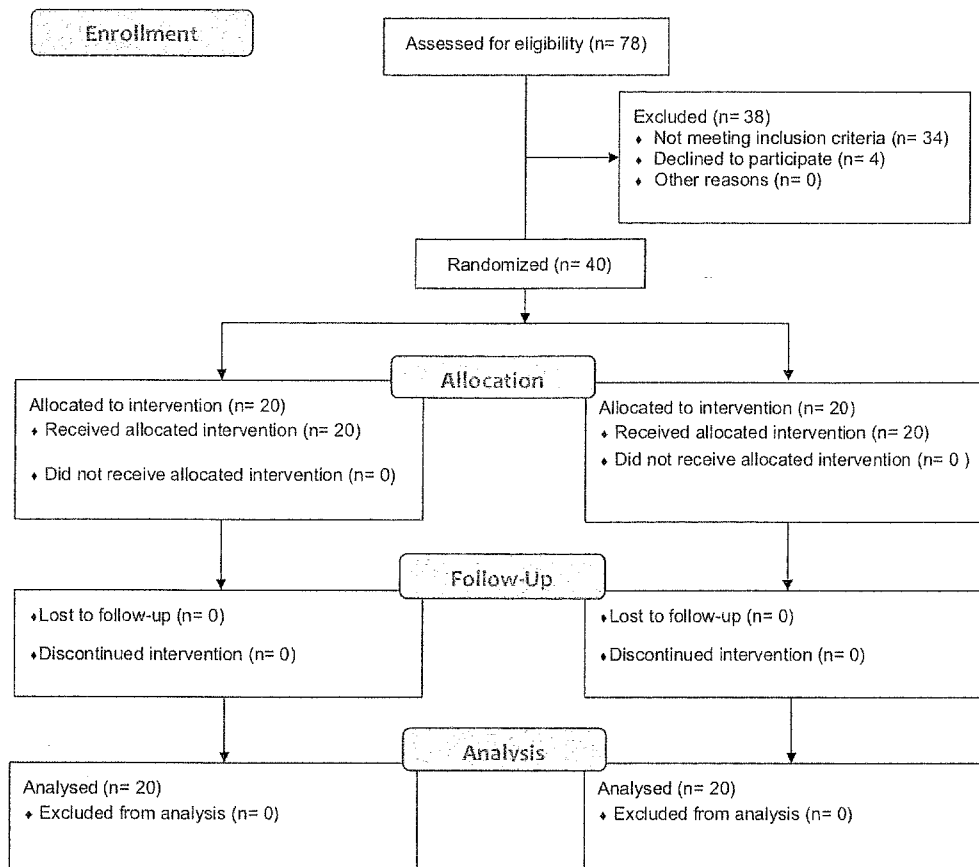


Fig. 1. Study flow-chart.

improvement of inflammation clinical indexes. FMBS and GI were already improved in Bioptron light group after 1 month. The wavelengths of Bioptron light, including the visible and the infrared spectrum, are compatible with the acceleration and improvement of blood supply and with the release of macrophage secreted growth factor (MSGF) that can stimulate fibroblast proliferation (11). The current literature (7-10) demonstrates the advantage of visible light therapy for skin injuries and diseases with the photobiomodulation, in which light at low energy levels modulates intra- and extra-cellular photoreceptors by molecular and cellular processes that can stimulate both anti-inflammatory mechanisms and cell proliferative homeostasis. To the best of our knowledge, no similar studies have been conducted to evaluate the use of polarized, polychromatic, non-coherent light for periodontal treatment.

Nevertheless, low level laser therapy (LLLT) has been demonstrated to enhance mechanical periodontal

treatment; LLLT in addition to FMSRP led to significantly lower periodontal and bleeding indexes and reduced PPD, and was proved to inhibit some subgingival bacteria (especially *Porphyromonas gingivalis*) (12).

Differences exist between these two adjunctive physical treatments. Like LLLT, Bioptron is also a low-power light source, but contrary to that it is polychromatic and incoherent rather than monochromatic and coherent. In fact, LLLT commonly employs red and near infrared light (600 nm-1000 nm), while polychromatic light wavelength is far wider (480-3400 nm). Bioptron delivers a power density of 0.04 W/cm², in line with LLLT devices (0.005-50 W/cm²). The Bioptron light beam has a wide diameter, allowing the exposure of larger anatomical areas simultaneously, otherwise, LLLT needs to be applied on site-by-site to be effective, requiring longer sessions and a steeper learning curve.

The improvements reached in our study confirm that SRP remain the gold standard therapy for periodontitis, as

all the clinical indexes were reduced, and almost all were statistically significantly reduced. The results confirm also the importance of a customized home maintenance protocol to improve oral health. Moreover, Bioptron light application is an effective adjunctive therapy combined with FMSRP, as our test group had a highly significant reduction of important clinical outcomes such as the GI and the FMBS.

Despite the accuracy of sample selection, data collection and statistical analysis, this study has the limit of a small sample and a short follow-up period, but the results encourage further studies on this technology applied to oral cavity.

REFERENCES

1. Nardi GM, Di Giorgio R, Sabatini S. Effectiveness of tips for delicate micro-ultrasonic root planing comparing to tips for traditional ultrasonic root planing. *Ann Stomatol (Roma)* 2012; 3(34):90-94.
2. Petersen PE, Ogawa H. Strengthening the prevention of periodontal disease: the WHO approach. *J Periodontol* 2005; 76(12):2187-93.
3. Sigmund SS, Haffajee AD, Teles R, et al. Effect of periodontal therapy on the subgingival microbiota over a 2-year monitoring period. I. Overall effect and kinetics of change. *J Clin Periodontol* 2013; 40(8):771-80.
4. Nardi GM, Sabatini S, Guerra F, Tatullo M, Ottolenghi L. Tailored Brushing Method (TBM): an innovative simple protocol to improve oral care. *J Biomed* 2016; 1:26-31.
5. Sabatini S, Ricci M, Candotto V, Lauritano D, Nardi GM. Effects of the application of high-pressure oxygen on the treatment of periodontal disease in diabetic patients. *Oral Implantol (Rome)* 2017; 10(4):412-23.
6. Sabatini S, Lauritano D, Candotto V, Silvestre FJ, Nardi GM. Oral probiotics in the management of gingivitis in diabetic patients: a double blinded randomized controlled study. *J Biol Regul Homeost Agents* 2017; 31(2 Suppl. 1):197-202.
7. Raeissadat SA, Rayegani SM, Rezaei S, Sedighipour L, Bahrami MH, Eliaspour D, Karimzadeh A. The effect of polarized polychromatic non-coherent light (Bioptron) therapy on patients with carpal tunnel syndrome. *J Lasers Med Sci* 2014; 5(1):39-46.
8. Stasinopoulos D. The use of polarized polychromatic non-coherent light as therapy for acute tennis elbow/lateral epicondylalgia: a pilot study. *Photomed Laser Surg* 2005; 23(1):66-69.
9. Durović A, Marić D, Brdareski Z, Jevtić M, Durdević S. The effects of polarized light therapy in pressure ulcer healing. *Vojnosanit Pregl* 2008; 65(12):906-18.
10. Aragona SE, Grassi FR, Nardi G, et al. Photobiomodulation with polarized light in the treatment of cutaneous and mucosal ulcerative lesions. *J Biol Regul Homeost Agents* 2017; 31(2 Suppl. 2):213-18.
11. Bolton P, Dyson M, Young S. The effect of polarized light on the release of growth factors from the u937 macrophage-like cell line. *J Stage* 1992; 4(1):33-37.
12. Ren C, McGrath C, Jin L, Zhang C, Yang Y. The effectiveness of low-level laser therapy as an adjunct to non-surgical periodontal treatment: a meta-analysis. *J Periodontal Res* 2017; 52(1):8-20.